

Case Studies: Freedom[®] Knee System

Real-World Outcomes in Primary and Revision Knee Arthroplasty

m a x x

orthopedics



Dr. Andrew C. Palmisano, MD

Orthopedic Surgeon, Ascentist Healthcare – Kansas City, MO

Dr. Palmisano is a board-certified orthopedic surgeon specializing in hip and knee replacement, including complex primary and revision arthroplasty. He practices at Ascentist Healthcare and affiliated hospitals throughout the Greater Kansas City area.

Education & Training

- MD – University of Toledo College of Medicine (2007–2011)
- Residency – Orthopedic Surgery, University of Michigan (2011–2016)
- Fellowship – Adult Reconstructive Surgery, Cleveland Clinic (2016–2017)

Certification & Professional Memberships

- Board Certified by the American Board of Orthopedic Surgery
- Member of the American Academy of Orthopedic Surgeons
- Member of the American Association of Hip & Knee Surgeons
- Member of the Missouri State Orthopedic Association

Clinical Focus

Dr. Palmisano provides advanced operative and non-operative treatments for joint pain and arthropathy. He is an active researcher, with published work on bone drilling safety, outcomes in transplant patients, and biomechanical analyses of orthopedic procedures. His findings have been presented at major conferences including AAOS, OTA, the Orthopedic Trauma Association, and Cleveland Clinic Research Day.

Leadership & Community Engagement

- Vice-Chair, Medical Executive Committee, Saint Luke's East
- Member, privileging and credentialing committee, Saint Luke's East
- Board Member, Arthritis Foundation – Kansas City

Practice Philosophy

Dr. Palmisano combines cutting-edge surgical expertise with compassionate, personalized care. He emphasizes patient education, shared decision-making, and achieving functional excellence—restoring mobility and helping patients return to active living. This is reflected in his outstanding patient satisfaction ratings.



Dr. Siraj A. Sayeed, MD, Meng

Orthopedic Surgeon & President, South Texas Bone & Joint Institute – San Antonio, TX

Dr. Sayeed is a board-certified, fellowship-trained orthopedic surgeon specializing in primary and complex total joint replacement of the shoulder, hip, and knee. As co-founder and President of South Texas Bone & Joint Institute, his mission is: “To personalize orthopedic total joint care, with compassion and integrity for each patient.”

Education & Training

- MD – University of Kentucky College of Medicine (1998-2002)
- Residency – Mayo Clinic, Rochester, MN (2002-2007)
- Fellowship – Rubin Institute for Advanced Orthopedics (2009-2010)
- Military Service – Served in the U.S. Air Force, including deployment to Afghanistan and as Chief of Total Joint Surgery at San Antonio Military Medical Center; achieved rank of Lieutenant Colonel (2007-2012)

Certification & Professional Memberships

- Board Certified by the American Board of Orthopedic Surgery
- Member of the American Academy of Orthopedic Surgeons
- Member of the American Association of Hip & Knee Surgeons
- Member of the Bexar County Medical Society, Texas Medical Association, and Texas Orthopedic Association

Clinical Focus

Dr. Sayeed’s expertise spans primary and revision joint arthroplasty—including minimally invasive, robotic, and tourniquet-free knee replacements, as well as direct anterior hip replacements. He has authored multiple peer-reviewed publications and serves on national orthopedic committees. He also holds academic appointments at SAMMC and UT Health San Antonio, actively involved in training future orthopedic surgeons.

Leadership & Community Engagement

- Vice-Chair, Medical Executive Committee, Saint Luke’s East
- Member, privileging and credentialing committee, Saint Luke’s East
- Board Member, Arthritis Foundation – Kansas City

Practice Philosophy

Dr. Sayeed combines precision surgical skill with compassionate, patient-centered care. He emphasizes individualized treatment plans, shared decision-making, and restoring patient confidence and quality of life through functional outcomes.

Case Study #1

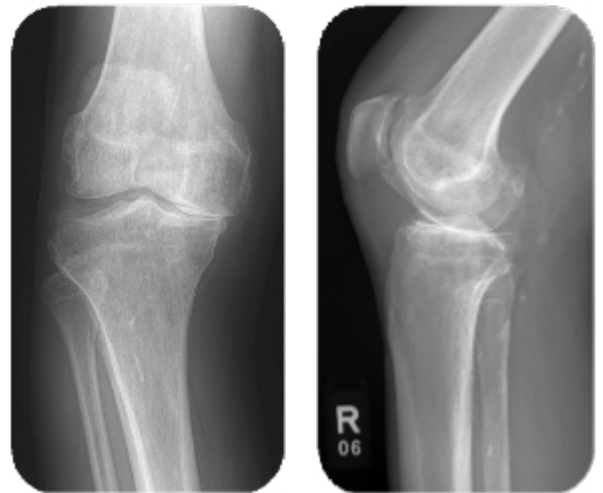Freedom® Primary Knee Restores Function in Varus Knee with Longstanding Arthritis

Surgeon: Dr. Siraj Sayeed

Institution: Methodist Hospital, San Antonio, TX

Patient Background

- Patient: 59-year-old female
- History: 20-year history of right knee pain diagnosed as severe degenerative arthritis.
- Conservative Treatments: Failed steroid injections, gel injections, physical therapy, gait aids, and multiple NSAIDs.
- Presentation:
 - Painful ROM (0–100°)
 - Varus alignment of right leg
 - Flexible deformity correctable with valgus stress
 - Difficulty walking more than 2 blocks due to pain

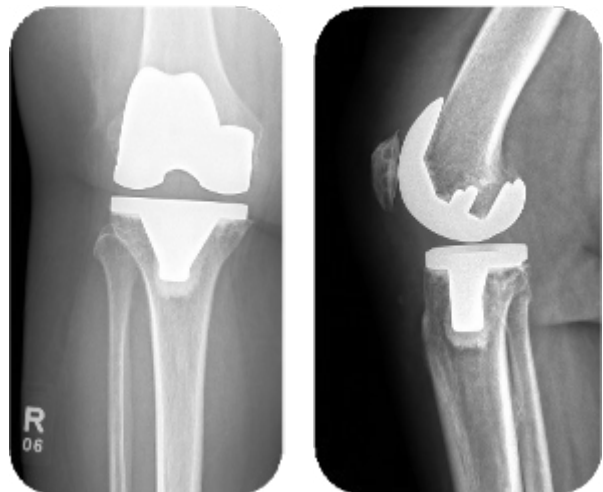


Diagnosis & Surgical Plan

- Diagnosis: End-stage right knee osteoarthritis with symptomatic varus malalignment
- Treatment: Right total knee arthroplasty using the Freedom® Primary Knee System to correct alignment, relieve pain, and restore function.

Surgical Highlights

- Procedure: Uncomplicated right TKA performed September 2024.
- Intraoperative Considerations:
 - Restoration of mechanical alignment.
 - Correction of flexible varus deformity through soft tissue balancing.
 - Achieved stable, well-aligned knee with full extension.



Outcome & Patient Recovery

- At Most Recent Follow-Up:
 - Pain reduced to 1/10
 - Painless ROM improved to 0–120°
 - Correction of varus deformity achieved
 - Ambulating comfortably, returned to the gym with treadmill walking >30 minutes
- Patient Satisfaction: Very pleased with ability to walk longer distances and resume fitness activities.

Conclusion

This case underscores how the Freedom® Knee System provides predictable correction of varus deformities and rapid functional recovery, enabling patients to return to active lifestyles with minimal pain.

Case Study #2

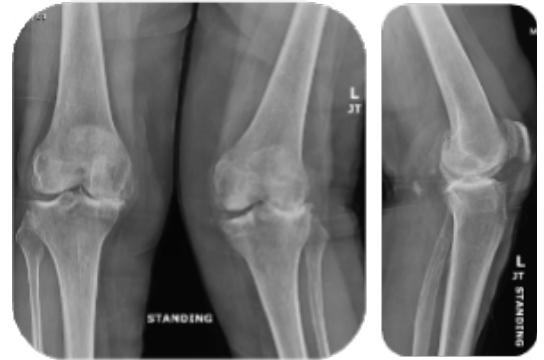
Freedom[®] UC TKA for Severe Valgus Knee Deformity and Instability

Surgeon: Dr. Andrew Palmisano

Institution: Ascentist Hospital, Kansas City, MO

Patient Background

- Patient: 72-year-old female, 5'4", 165 lbs
- History:
 - Progressive valgus deformity of the left knee with worsening pain and dysfunction
 - Failed non-operative management including medications and therapy

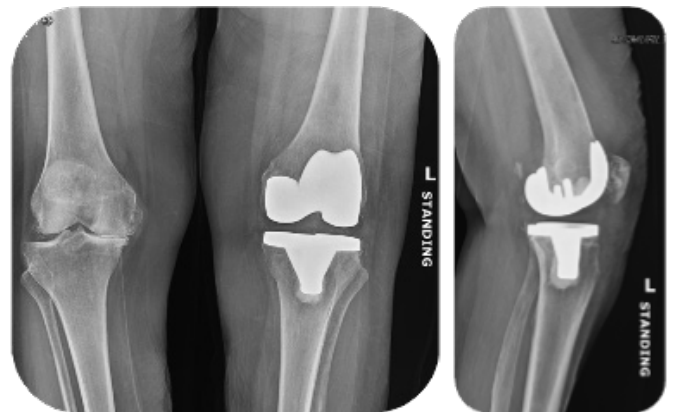


Diagnosis & Surgical Plan

- Diagnosis: Severe end-stage left knee DJD with significant valgus malalignment
- Treatment: Left total knee arthroplasty using Freedom[®] UC to restore alignment, stability, and reduce pain.

Surgical Highlights

- Implants Used:
 - Femur: Size C
 - Tibia: Size 4
 - Insert: 14 mm UC
 - Patella: 28 mm resurfacing
- Key Intraoperative Measures:
 - Managed low bone density and severe valgus anatomy with readiness to up-constrain (PCK, augments available)
 - Adjusted cuts for increased native slopes due to deformity
 - Paid close attention to patellar tracking, performing a partial lateral release and medializing the patella component to optimize alignment



Outcome & Patient Recovery

- Post-Op Course:
 - Discharged on POD1 with home health; transitioned to outpatient PT at week 2
 - Uncomplicated wound healing
- At 3-Month Follow-Up:
 - ROM: 0–125° with neutral alignment
 - Knee stable throughout arc of motion
 - Ambulating without assistive devices, off pain medications
 - Returned to daily activities as tolerated

Conclusion

This case highlights the ability of the Freedom[®] UC system to correct severe valgus deformity and provide a stable, well-aligned knee in patients with challenging bone quality—restoring pain-free motion and functional independence.

Case Study #3

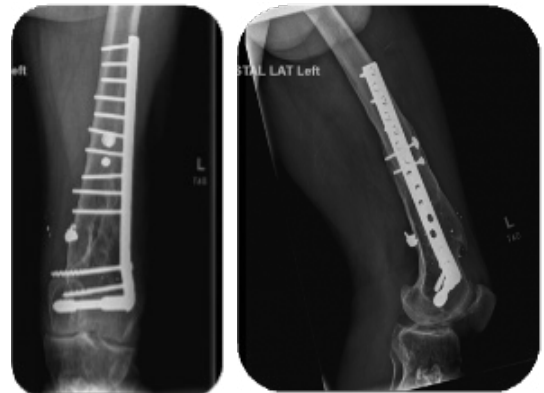
Freedom® UC TKA in Post-Traumatic Arthritis with Fixed Deformity and Retained Hardware

Surgeon: Dr. Andrew Palmisano

Institution: Ascentist Hospital, Kansas City, MO

Patient Background

- Patient: 59-year-old male, 5'6", 208 lbs
- History:
 - Previous gunshot wound to left distal thigh/knee with healed scars
 - Developed progressive post-traumatic degenerative joint disease with fixed deformity
 - Failed conservative management including medications and therapy

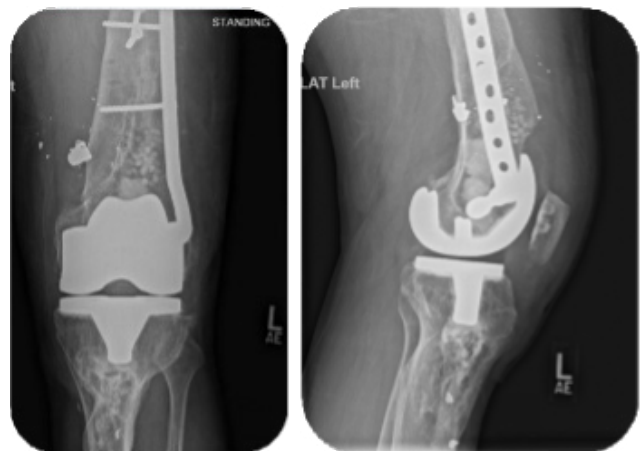


Diagnosis & Surgical Plan

- Diagnosis: Severe end-stage post-traumatic DJD of the left knee
- Treatment: Left total knee arthroplasty with hardware removal, using the Freedom® UC system to address deformity and restore function.

Surgical Highlights

- Implants Used:
 - Femur: Size H
 - Tibia: Size 7
 - Insert: 9 mm UC
 - Patella: 31x9 mm resurfacing
- Key Intraoperative Measures:
 - Managed retained hardware and planned for potential partial plate extraction
 - Addressed bone loss and fixed deformity; adjusted slope for altered anatomy
 - Cannulated femoral canal carefully due to previous injury
 - Medialized patella implant to optimize tracking
 - Ensured availability of higher constraint implants if needed



Outcome & Patient Recovery

- Post-Op Course:
 - Discharged POD2 with home health; transitioned to outpatient PT by week 2
 - Uncomplicated wound healing
- At 3-Month Follow-Up:
 - ROM improved to 0–110°
 - Walking unassisted, off pain medications
 - Returned to work as a roofer

Conclusion

This case illustrates the flexibility of the Freedom® UC system in managing complex post-traumatic arthritis with prior hardware, fixed deformity, and scarred soft tissues—restoring alignment, stability, and function even in demanding occupational patients.

Case Study #4

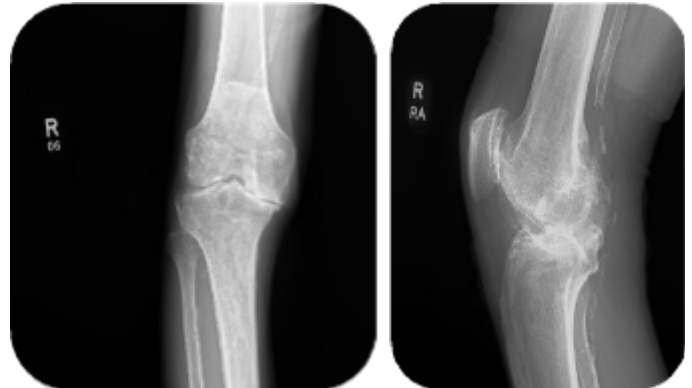
Freedom® Primary Knee for Severe Varus Deformity Restoring Independent Ambulation

Surgeon: Dr. Siraj Sayeed

Institution: Methodist Hospital, San Antonio, TX

Patient Background

- Patient: 67-year-old male
- History:
 - 13-year history of right knee pain with progressive decline
 - Diagnosed with severe degenerative arthritis
 - Failed conservative treatments including injections, physical therapy, gait aids, NSAIDs

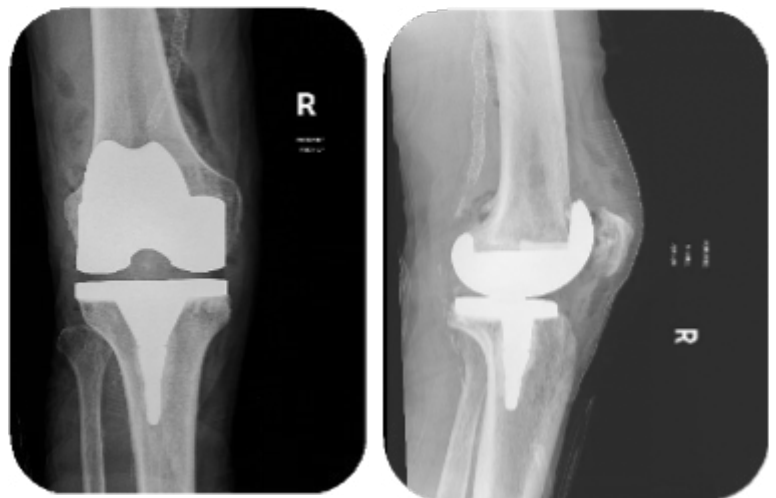

Diagnosis & Surgical Plan

- Diagnosis: End-stage right knee osteoarthritis with severe fixed varus deformity
- Presentation:
 - Painful ROM 0–90°
 - Fixed varus alignment without MCL laxity
 - Unable to bear weight for long distances, reliant on motorized scooter
- Treatment: Right total knee arthroplasty using the Freedom® Primary Knee system to correct alignment, restore motion, and eliminate assistive device dependence.

Surgical Highlights

- Procedure: Uncomplicated right TKA performed February 2025
- Key Intraoperative Considerations:
 - Managed significant fixed varus deformity with careful soft tissue balancing
 - Corrected mechanical alignment to offload medial compartment
 - Achieved stable, well-tracking knee without additional constraint required



Outcome & Patient Recovery

- At Most Recent Follow-Up:
 - Pain improved to 1/10
 - Painless ROM 0–120°
 - Full correction of varus deformity
 - No longer reliant on scooter—ambulating independently

Conclusion

This case demonstrates how the Freedom® Knee reliably corrects severe fixed varus deformities, enabling patients to regain independent mobility, significant pain relief, and improved quality of life.

Case Study #5

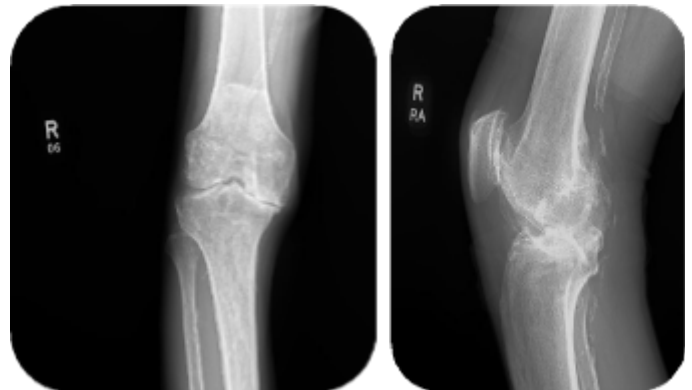
Freedom® Primary Knee Corrects Severe Valgus Deformity and Restores Pain-Free Motion

Surgeon: Dr. Siraj Sayeed

Institution: Methodist Hospital, San Antonio, TX

Patient Background

- Patient: 74-year-old female
- History:
 - 3-year history of right knee pain with progressive worsening
 - Diagnosed with severe degenerative arthritis and valgus deformity
 - Failed conservative measures including injections, physical therapy, gait aids, multiple NSAIDs, and two geniculate nerve blocks



Diagnosis & Surgical Plan

- Diagnosis: Severe right knee osteoarthritis with flexible valgus deformity
- Presentation:
 - Painful ROM 0–110°
 - Valgus alignment correctable with varus stress
 - Difficulty walking even 1 block due to pain
- Treatment: Right total knee arthroplasty using the Freedom® Primary Knee system to restore mechanical alignment and relieve pain.

Surgical Highlights

- Procedure: Uncomplicated right TKA performed June 2024
- Key Intraoperative Considerations:
 - Corrected valgus alignment through soft tissue balancing and precise cuts
 - Ensured stable tracking and maintained full extension and flexion without residual laxity
 - Achieved optimal component positioning to support long-term function



Outcome & Patient Recovery

- At Most Recent Follow-Up:
 - Pain completely resolved (0/10)
 - Painless ROM improved to 0–120°
 - Full correction of valgus deformity with stable, well-aligned knee

Conclusion

This case highlights the predictable results of the Freedom® Knee system in correcting severe valgus deformities, restoring pain-free range of motion, and enabling patients to regain mobility and confidence.

Case Study #6

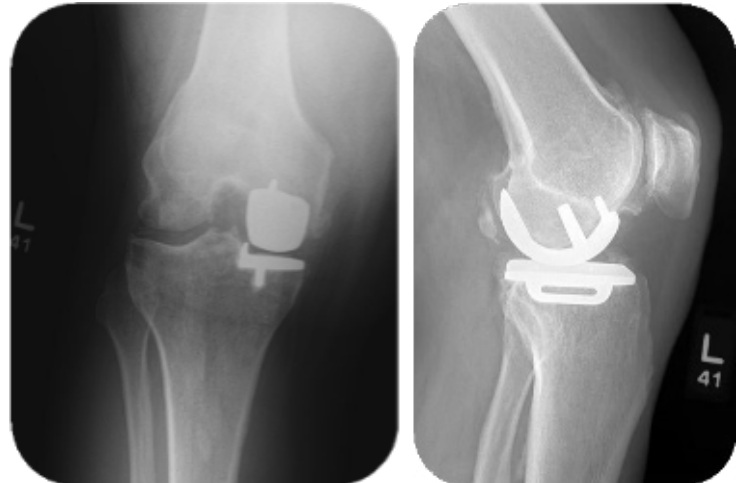
Freedom® Knee Conversion of Symptomatic UKA Restores Motion and Confidence

Surgeon: Dr. Siraj Sayeed

Institution: Methodist Hospital, San Antonio, TX

Patient Background

- Patient: 66-year-old male
- History:
 - Initially treated with medial unicompartmental arthroplasty (UKA) in February 2022 for isolated medial arthritis
 - Developed painful ROM (0–110°) with significant patellar crepitus, positive grind test, and new lateral compartment pain
 - Workup negative for infection

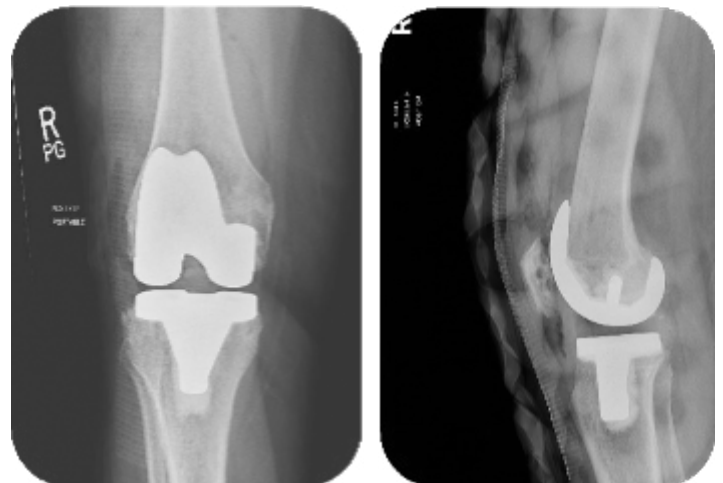


Diagnosis & Surgical Plan

- Diagnosis: Failed medial UKA with progression to lateral compartment disease and patellofemoral pathology
- Presentation:
 - 8/10 knee pain
 - Instability and inability to trust the knee during activities
- Treatment: Conversion of left medial UKA to total knee arthroplasty using the Freedom® Knee system to address global disease and instability.

Surgical Highlights

- Procedure:
 - Uncomplicated UKA-to-TKA conversion performed March 2025
 - Managed residual bone defects and optimized component positioning to restore joint mechanics
 - Ensured balanced flexion and extension gaps to achieve stable, full-range function



Outcome & Patient Recovery

- At Most Recent Follow-Up:
 - Pain significantly reduced to 3/10
 - Full, painless ROM 0–120°
 - Patient reports restored confidence in knee stability and is highly satisfied with outcome

Conclusion

This case highlights the Freedom® Knee's effectiveness in addressing failed unicompartmental knees, restoring stable kinematics, reducing pain, and enabling patients to return to daily activities with renewed trust in their joint.

Case Study #7

Freedom® Knee Revision Restores Stability and Eliminates Pain in Grossly Unstable Knee

Surgeon: Dr. Siraj Sayeed

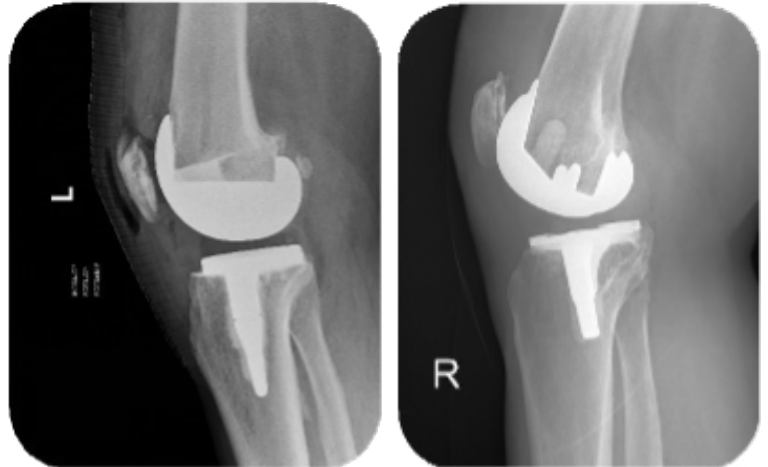
Institution: Methodist Hospital, San Antonio, TX

Patient Background

- Patient: 73-year-old male
- History:
 - Presented with 7/10 chronic right knee pain
 - Experienced multiple daily instability episodes
 - Workup ruled out infection

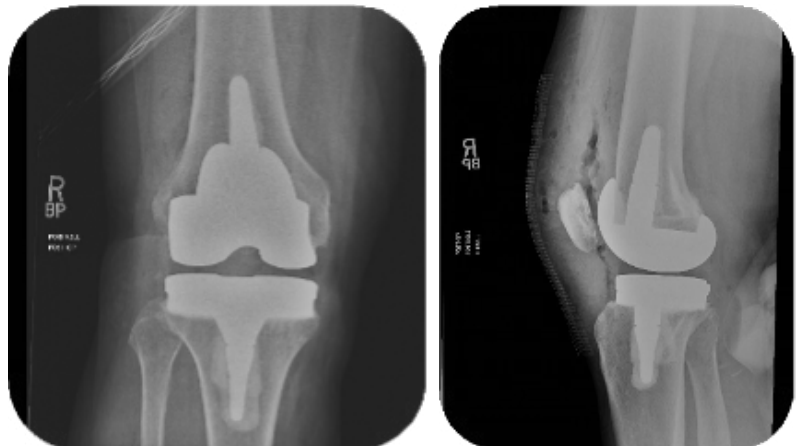
Diagnosis & Surgical Plan

- Diagnosis: Grossly unstable right knee post-arthroplasty, with pain and mechanical instability
- Presentation:
 - ROM limited to 10–90° with pain
 - Marked varus and valgus instability on stress testing
- Treatment: Revision TKA using the Freedom® Knee system to re-establish stability, restore function, and relieve pain.



Surgical Highlights

- Procedure: Right knee revision TKA performed with Freedom® components to address multi-planar instability
- Key Intraoperative Focus:
 - Comprehensive soft tissue balancing and secure implant fixation
 - Achieved stable construct under varus and valgus stress
 - Ensured improved range and alignment throughout arc of motion



Outcome & Patient Recovery

- At 6-Month Follow-Up:
 - Pain resolved (0/10)
 - ROM improved to 0–120° and painless
 - No further episodes of instability
 - Patient highly satisfied with outcome

Conclusion

This case underscores the capability of the Freedom® Knee system to reliably restore stability and function in complex revision scenarios involving gross multi-directional instability, delivering rapid return to pain-free daily activities.

Case Study #8

Successful Freedom® PCK Revision in a Complex Arthrofibrosis Case

Surgeon: Dr. Andrew Palmisano

Institution: Ascentist Hospital, Kansas City, MO

Patient Background

- Patient: 73-year-old male, 5'10", 200 lbs
- History: Prior right total knee arthroplasty (TKA) with progressive stiffness and pain.
- Presentation:
 - Severe loss of motion (ROM 10–6°, firm endpoint)
 - Pain throughout range of motion
 - Mild midflexion instability
 - Strength 5/5; neurovascularly intact

Diagnosis & Surgical Plan

- Diagnosis: Failed right TKA with arthrofibrosis
- Treatment: Revision TKA using the Freedom® PCK system to address stiffness, instability, and restore functional range.

Surgical Highlights

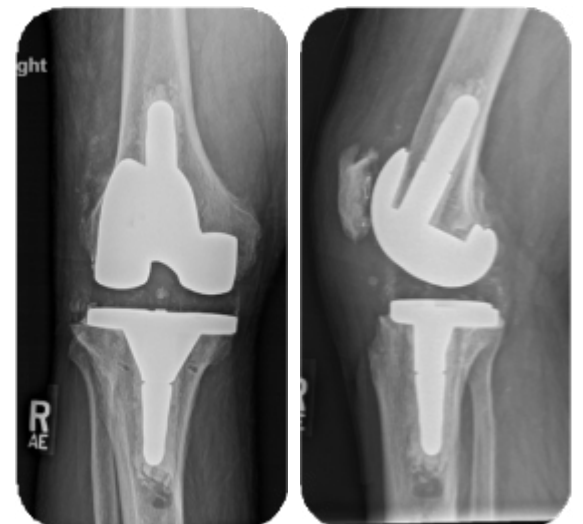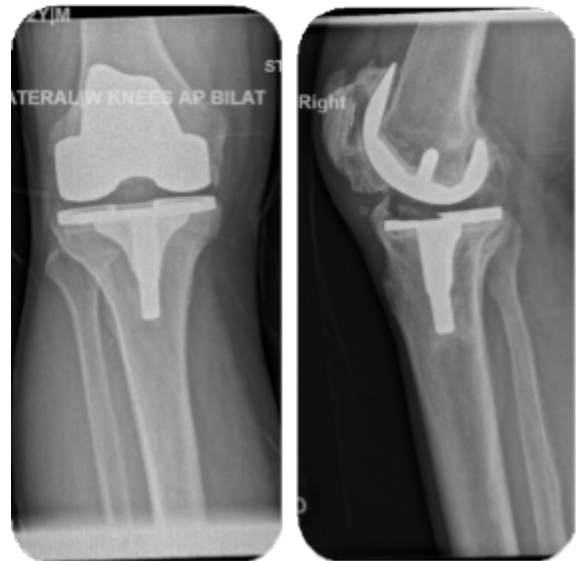- Implants Used:
 - Femur: E PCK with 40x15 mm stem
 - Tibia: Size 6 with 40x12 mm stem
 - Insert: 17 PCK
 - Patella: Retained native patella
- Key Surgical Considerations:
 - Careful, deliberate implant extraction to protect collateral ligaments and conserve bone.
 - Removal of excess bone formation to improve motion and patellar tracking.
 - Distal quadriceps tendon release from anterior femur to optimize flexion.

Outcome & Patient Recovery

- Hospital Course: Discharged on POD2 with outpatient physical therapy.
- At 3 months post-op:
 - ROM improved to 5–110°
 - Stable arc of motion with no instability
 - Ambulating unassisted
 - Returned to hunting and fishing without prior limitations.

Conclusion

This case demonstrates how the Freedom® PCK system effectively manages complex revision scenarios with stiffness and instability. Thoughtful intraoperative technique combined with a versatile implant system enabled restoration of function, stability, and quality of life.



Case Study #9

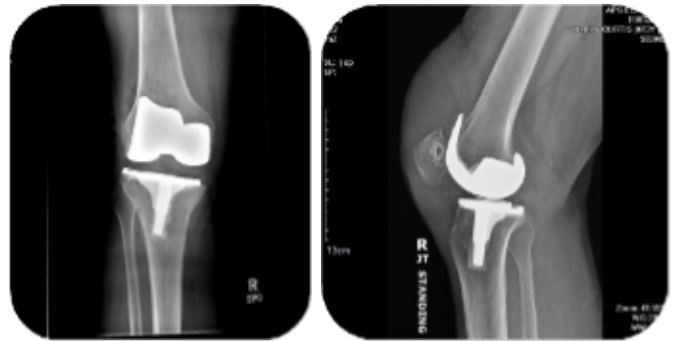
Freedom® PCK Revision for Patellar Subluxation and Instability After Prior TKA

Surgeon: Dr. Andrew Palmisano

Institution: Ascentist Hospital, Kansas City, MO

Patient Background

- Patient: 73-year-old male, 6'1", 200 lbs
- History:
 - Previous right primary TKA complicated by instability and pain
 - Underwent polyethylene exchange and arthroscopy
 - Developed chronic large effusion with medial retinacular disruption
 - Progressive pain, decreased extensor strength, and recurrent dysfunction
 - Failed conservative treatments

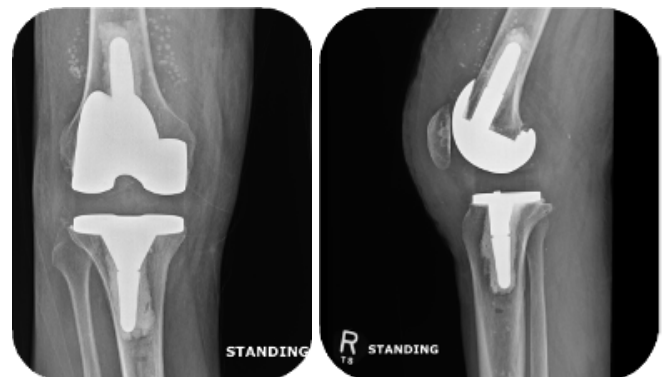

Diagnosis & Surgical Plan

- Diagnosis: Failed right total knee arthroplasty with medial retinacular disruption and lateral patellar subluxation
- Treatment: Revision TKA using Freedom® PCK to address instability, patellar maltracking, and restore function.

Surgical Highlights

- Implants Used:
 - Femur: G PCK, 15x40 mm stem, 5 mm posterior medial/lateral augments
 - Tibia: Size 6, 12x40 mm stem
 - Insert: 23 mm PCK
 - Patella: 31x9 mm resurfacing
- Key Intraoperative Measures:
 - Confirmed no periprosthetic infection (labs) prior to proceeding
 - Managed bone loss and instability with modular augments and stems
 - Redefined medial tissue planes for patellar realignment and secure capsular closure
 - Placed antibiotic beads in the wound before final closure



Outcome & Patient Recovery

- Post-Op Course:
 - Discharged on POD1 with home health, transitioned to outpatient PT by week 2
 - Uncomplicated wound healing
- At 6-week Follow-Up:
 - ROM: 0–120°
 - Discontinued all pain medications
 - Well-tracking patella with no recurrent effusion

Conclusion

This case demonstrates the adaptability of the Freedom® PCK system in managing complex revision challenges, including instability and chronic patellar subluxation, restoring alignment and function for sustained patient recovery.

Freedom® Total Knee System

Total Knee Arthroplasty

Freedom® Knee System showcases a modern design that factors in shape, bone conservation, flexion range, size, and clinical environment to meet surgical demands and comprehensive needs of active lifestyles in today's patients. It offers numerous poly insert options- CR, PS, UC, and MC- and features a 5-chamfer femoral design, thin anterior flange, and a low-profile tibial keel.



Freedom® Primary PCK™ Knee System is ideal for Complex Primary knee cases. It features a taller box design compared to standard Freedom PS Knee System and can be used with a tibial stem for greater stability when needed.

Freedom® PCK® Knee System

Revision Knee Arthroplasty

Freedom® PCK Revision Knee System features a patented trapezoidal box that delivers progressive constraint kinematics (PCK) and is designed to restore knee function and motion in revision knee patients.

Freedom® Titan™ PCK Revision Knee System utilizes the same design and instruments as Freedom PCK but has a TiNbn ceramic coating for patients with metal hypersensitivity.

Both systems feature:

Progressive Constraint – Trapezoidal femoral box maintains stability in extension while allowing controlled motion in flexion.


Natural Kinematics – Replicates normal knee movement by balancing constraint and rotational freedom.


Modular & Versatile – Ti-alloy stems and stackable augments provide intraoperative flexibility to address bone defects

Ti-alloy stems (cemented & press fit)

7.5mm-20mm diameters 40mm, 75mm, 100mm, 150mm lengths









Products from Maxx Orthopedics may not be available in all markets. Please contact your Maxx Orthopedics representative or distributor if you have questions regarding availability in your area.

Maxx Orthopedics, Inc.
2460 General Armistead Ave. Ste #100
Norristown, PA 19403
Email: info@maxxortho.com

www.maxxortho.com
©2025 Maxx Orthopedics, Inc.
MXO-MP00070 R01 07/25